

LUMBAR MUSCLE FUNCTION AND DYSFUNCTION IN LOW BACK PAIN

Markku Kankaanpää

*Department of Physical Medicine and Rehabilitation, Kuopio University Hospital, and
Department of Physiology, University of Kuopio, Finland*

Keywords: Low back pain, trunk muscles, muscle coordination, dysfunction, biomechanics, deconditioning syndrome.

Contents

1. Anatomy and Function of the Trunk Extensor and Flexor Muscles
 - 1.1. Functional Properties of Lumbar Spine
 - 1.2. Anatomy of Lumbar and Abdominal Muscles
 - 1.3. Control Properties of Lumbar and Abdominal Muscles
 2. Epidemiological Aspects of LBP
 - 2.1. Physical Risk Factors of LBP
 3. Structural and Pathophysiological Aspects in LBP
 4. Lumbar Muscle Dysfunction in LBP
 - 4.1. Loss of Strength
 - 4.2. Excessive Lumbar Muscle Fatigue
 - 4.3. Loss of Co-ordination and Muscle Control
 - 4.4. Active Rehabilitation and Back Extensor Muscle Functional Assessment
- Glossary
Bibliography
Biographical Sketch

Summary

Low back pain is one of the most common health problems. The reason for back pain is most often unknown. Some of the models that help in explaining the origin of low back pain are introduced. The lumbar structure and muscle functions and dysfunctions in relation to low back pain are reviewed. Complex central and peripheral elements control the biomechanics of the lumbar spine and ensure optimal spinal loading in normal everyday life situations. Low back pain leads to acute and chronic changes in paraspinal muscles and their control mechanisms. Acute changes are observed as impaired reflexive functions of paraspinal muscles. Pain in spinal structures results from reflexive activities that protect the spine from excessive and harmful loading. Chronic effects include more definitive changes in muscle structure and performance (strength and endurance). These functional deficiencies can be normalized by functional restoration in forms of active physical rehabilitation, which has been recently recognized as an effective treatment for low back pain.

1. Anatomy and Function of the Trunk Extensor and Flexor Muscles

1.1 Functional Properties of Lumbar Spine

The principal movements of the human lumbar spine are flexion, extension, lateral flexion, axial rotation, axial compression and axial distraction. These six degrees of freedom allow the spine to undergo the desired movements in three-dimensional space. The basis for these movements lie in the function of the intervertebral joints joining the two vertebrae, also collectively called a functional spinal unit (FSU). This consists of two vertebrae with a flexible disc (intervertebral disc) in between, and the attached ligaments and muscles, respectively termed as passive and active elements. The structure is viscoelastic, and it allows the FSU to undergo three-dimensional movements by coupling rotation and translation movements in sagittal, horizontal and coronary planes. However, the orientation of the lumbar zygapophyseal joints limits axial rotation. Due to the nature of these three dimensional motions, complex loading patterns act on the passive structures of osteoligamentous FSU, and if unprotected, the unit is vulnerable to damage. Therefore it is fundamental that these motions are precisely guarded by lumbar and abdominal muscles in order to produce the required stiffness and optimize the loading on lumbar spine, and prevent overload and injury. For example, the human osteoligamentous lumbar spine becomes mechanically unstable *in vitro* under a compressive load of approximately 90 Newtons, a load far less than the weight of the upper body. It has been experimentally shown that lumbar multifidus muscles are the most important back muscles in providing the required stiffness for the lumbar spine.

1.2 Anatomy of Lumbar and Abdominal Muscles

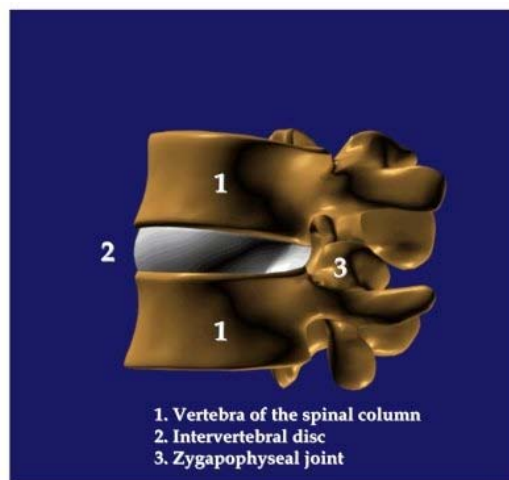
The lumbar back muscles lie behind the vertebral transverse processes, cover the posterior elements of the lumbar spine and exert their actions on the lumbar spine. The main mass of the lumbar back muscles is formed by lumbar erector spinae and multifidus muscles. They are all innervated by primary dorsal rami of the spinal nerves.

The erector spinae muscle has lateral and medial divisions, which are named iliocostalis lumborum and longissimus thoracis, respectively. Both of these divisions have fascicles arising from lumbar or thoracic vertebrae (Figure 1).

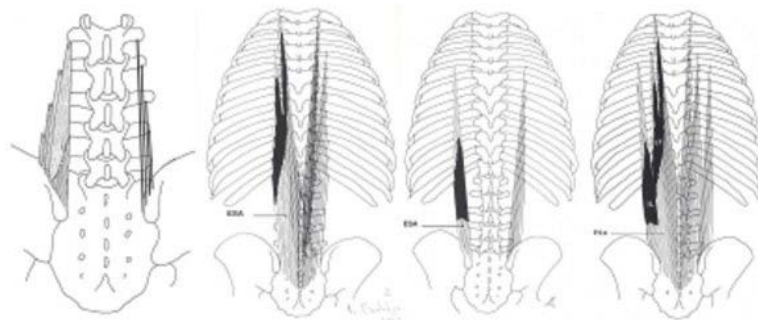
Lateral division. The lumbar part of the iliocostalis lumborum muscle is composed of four overlying fascicles arising rostrally from the lateral ends of the L1 to L4 transverse processes and the middle layer of the thoracolumbar fascia, caudally attaching to the iliac crest. The L5 fascicle is the iliolumbar ligament. A bilateral contraction of the lumbar part of the iliocostalis lumborum produces posterior sagittal rotation and posterior translation of the lumbar vertebrae, and as a result, extension of the lumbar spine. The unilaterally lumbar part of the iliocostalis lumborum can act as a powerful lateral flexor and axial rotator of the lumbar vertebrae. The fascicles of the thoracal part of the iliocostalis lumborum arise from the lower seven ribs and form the long caudal tendons, which collectively create the lateral part of the erector spinae aponeurosis that is attached to the iliac crest. A bilateral contraction produces an increase in the lumbar lordosis and powerful extension of the spine. A unilateral contraction results in the lateral flexion and axial rotation.

Medial division. The lumbar part of the longissimus dorsi muscle is composed of five fascicles that run from the accessory and transverse processes of each lumbar vertebra to the posterior superior iliac spine. The L5 fascicle is shortest and deepest. The bilateral

contraction produces posterior translation and sagittal rotation of their vertebrae of origin, and as a result, extension of the lumbar spine. A unilateral contraction flexes the vertebral column laterally and produces a weak axial rotation. The thoracal part of the longissimus muscle consists of 11 to 12 pairs of small fascicles arising from the ribs and transverse processes of the thoracal vertebrae, which are attached caudally to the lumbar spinal processes and to the posterior surface of the sacrum. Each muscle belly has a long caudal tendon, which joins to form the medial part of the erector spinae aponeurosis. This aponeurosis covers the lumbar fibers of the longissimus and iliocostalis muscles. Their bilateral contraction increases the lumbar lordosis but the unilateral contraction produces lateral flexion of the thoracal spine and also lateral flexion of the lumbar spine.



(a)



(b)

Figure 1 A) Functional spinal unit (FSU) consisting two vertebrae and a flexible intervertebral disc in between. B) The iliocostalis lumborum (lateral division) and longissimus thoracis (medial division) muscles of the erector spinae muscle. From left to right: Lumbar and thoracal parts of iliocostalis lumborum muscles, and lumbar and thoracal parts of longissimus thoracis muscles. ESA = erector spinae aponeuroses.

The multifidus muscles are spinotransverse muscles. The multifidus muscle mass consists of five overlapping muscle fascicles (see Figure 2). The shortest and deepest laminar fascicles connect each lumbar lamina with the mammillary processes two levels caudally from their origin. The other fascicles connect each spinal process with mammillary

processes two to five vertebrae caudally. The fascicles are oriented caudally and laterally at an angle of 15° in men and 24° in women. In a lateral view, the multifidus fascicles are oriented at a right angle to their spinal processes of origin. All fascicles stemming from one spinal process are innervated by the same dorsal ramus of the respective spinal nerve that originates from below that vertebra. The main multifidus action is posterior sagittal rotation of the lumbar vertebrae, and they are strong stabilizers of the lumbar vertebrae. Unilateral contraction produces a weak axial rotation.

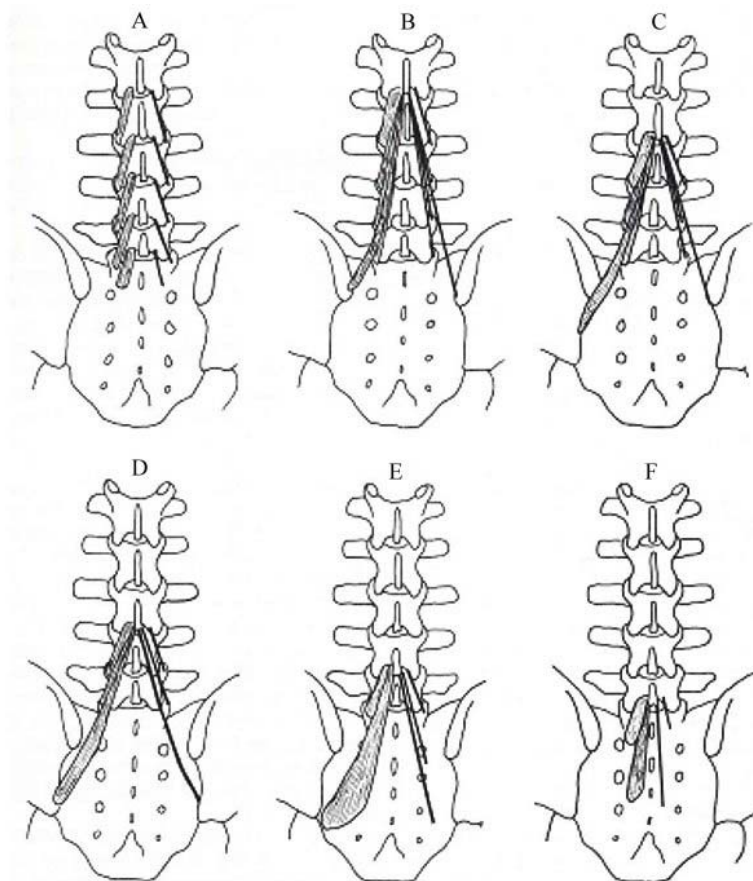


Figure 2. The fascicles of multifidus muscles: the laminar fibers (A), and the fascicles from the L1 to L5 spinous processes respectively (B to F).

Interspinal muscles are small-paired muscles that connect the spinal processes between their lateral surfaces. Their muscle mass is small and would not, therefore, contribute greatly to the sagittal rotation of the lumbar vertebra. It has been suggested that their function could be better described in terms of proprioception, since they contain a five to six fold higher density of muscle spindles than the larger back extensor muscles.

The quadratus lumborum is a wide rectangular shaped muscle that arises from the 12th rib and lumbar transverse processes. Caudally it attaches to the top margin of the ilium. The main function of the muscle is to produce the lateral flexion of the trunk. Furthermore, it has also been claimed to take a part in respiration.

Psoas major and minor muscles cover the anterolateral portions of lumbar spine. The psoas major muscle arises from the anterolateral aspect of lumbar spine and inserts into the lesser trochanter of the femur. The psoas minor muscle arises from the T12-L1 intervertebral disc and attaches to an iliopubic eminence via a narrow tendon. Unlike dorsal lumbar muscles, the psoas muscles are strong flexors of the trunk.

Abdominal muscles form a sheath at the anterior portion of the abdomen, abdominal wall. Rectus abdominis is a paired straight vertical muscle arising from the cartilages of the 5th-7th ribs extending caudally and attaching to the pubic crest. The lateral abdominal wall is covered by internal and external oblique as well as transversus abdominis muscles, the latter being the most superficial. All abdominal muscles, especially rectus abdominis, produce trunk flexion. Internal and external oblique and transversus abdominis muscles are capable of producing trunk rotation, flexion and lateral flexion. This is because of their orientation anterolaterally and caudally.

The thoracolumbar fascia consists of three separate layers that encase the lumbar back muscles and connects anteriorly via a lateral raphe with the transversus abdominis and oblique muscles. Posteriorly the thoracolumbar fascia is continuous with the latissimus dorsi and gluteus maximus muscles. Also this fascia connects caudally with the sacrotuberous ligament, which enables an indirect link to the biceps femoris muscles. The function of the thoracolumbar fascia along with the attached muscles and bone structures plays an important role in transferring the load between the trunk and legs during trunk flexion and extension.

-
-
-

TO ACCESS ALL THE 12 PAGES OF THIS CHAPTER,
Visit: <http://www.eolss.net/Eolss-sampleAllChapter.aspx>

Bibliography

Basmajian J.V. and DeLuca C.J. (1985). *Muscles Alive: Their Functions Revealed by Electromyography*. Williams & Wilkins, Baltimore London Sydney, pp. 65-222, 354-366. [Basic concepts of electromyography detection, recording and interpretation, and lumbar muscle dysfunction in relation to low back pain].

Bogduk N. and Twomey L.T. (1991). *Clinical Anatomy of the Lumbar Spine*, 53-105. Churchill Livingstone, Melbourne. [Spine anatomy and basic biomechanics].

Cram J. and Kasman G. (Eds). (1998). *Introduction to Surface Electromyography*. Aspen Publication, Gaithersburg, MD, [Basic concepts of electromyography detection, recording and interpretation].

Jørgensen K. (1997). *Human Trunk Extensor Muscles: Physiology and Ergonomics*. Acta Physiologica Scandinavica, Suppl 637, Academic dissertation. [Trunk muscle anatomical and functional deficiencies related to low back pain].

Rothwell J.C. (1994). Proprioceptors in muscles, joints and skin. In: *Control of Human Voluntary Movement*. Second edition. Chapman & Hall, London, pp. 86-126 [Proprioceptive and reflexive functions of the lumbar spine].

Van Tulder M.W., Assendelft W.J.J., Koes B.W. and Bouter L.M. (1997). Spinal radiographic findings and nonspecific low back pain. A systematic review of observational studies. *Spine* 22, 427-434, [Radiological considerations in low back pain].

Van Tulder M.W., Malmivaara A., Esmail R. and Koes B.W. (2002). Exercise therapy for low back pain (Cochrane Review). Cochrane Library number: CD000335. In: *The Cochrane Library*, Issue 3, Oxford, Update Software. [Active rehabilitation as treatment for low back pain].

Wiesel S.W., Weinstein J.N., Herkowitz H., Dvorak J. and Bell G. (1996). *The Lumbar Spine*, Volume 1 & 2. Second edition. W.B Saunders company, Philadelphia, pp. 1042-1056, 1074-1105. [Trunk performance measurement methods and conservative treatment approaches for low back pain].

Biographical Sketch

Dr Markku Kankaanpää, DMS was born in 1966 in Lapua, Finland. He is specialist in Physical and Rehabilitation Medicine and currently working as post doc researcher in the Department of Physical and Rehabilitation Medicine, Kuopio University Hospital, Kuopio, Finland. He studied at the University of Kuopio, where he received his Licentiate of Medicine (MD) and Doctor of Medical Sciences (DMS) in 2000. His special interests in research are lumbar disorders, especially active rehabilitation, motor control, muscle physiology, and myoelectric alterations related to low back pain and Parkinson's disease.

He has contributed 25 papers in refereed journals.