

## **BILHARZIASIS: A GRANULOMATOUS PARASITIC DISORDER WITH GRAVE IMPLICATIONS**

**Maha Mahmoud Akl**

*Department, Theodor Bilharz Research Institute (affiliated to Ministry of High Education and Scientific Research). Kornish El Nile. Warak El Hadar, Embaba, Cairo. Egypt P.O.Box 30. Postal Code: 12411.*

**Keywords:** Bilharziasis, Schistosomiasis granulomas, parasitic disorder, splenomegaly, sandy patches, esophageal varices, caput medusa, liver fibrosis.

### **Contents**

1. Introduction
  - 1.1 Discovery of schistosomes ( Bilharzia worms) by Theodor Bilharz
2. Life cycle of the Bilharzial parasite
  - 2.1 Schistosomiasis species and their stages
  - 2.2. Asexual part of life cycle (intermediate host phase)
  - 2.3. Sexual part of the cycle
  - 2.4. Eggs
3. Pathogenesis of Schistosomiasis
  - 3.1. Eggs
  - 3.2. Egg granulomas
  - 3.3. Mechanisms underlying granuloma formation
  - 3.4. Pathological stages of schistosomiasis
4. Clinical features of Bilharziasis due to Schistosoma mansoni infection
  - 4.1.Skin Lesions
  - 4.2. Acute schistosomiasis
  - 4.3. Intestinal Schistosomiasis (Bilharziasis); chronic stage
  - 4.4. Complications of Intestinal Bilharziasis: Includes the following
  - 4.5. Symptoms of Intestinal Bilharziasis
  - 4.6.Treatment of Intestinal Bilharziasis
5. Hepatosplenic Bilharziasis (Bilharzial hepatic fibrosis)
  - 5.1. Pathogenesis and Pathology of Bilharzial Hepatic Fibrosis
  - 5.2.Classification of Bilharzial Portal Fibrosis
  - 5.3. Effects of Bilharzial Portal Fibrosis and Its Complications
  - 5.4. Causes of Death in Hepatic Bilharziasis
6. Bilharziasis of the urogenital system
  - 6.1. Bilharzial Cystitis
  - 6.2. Pathogenesis of Bilharzial Cystitis
  - 6.3. Complications of Urinary Bilharziasis
  - 6.4. Bilharziasis of Other Parts of the Uro-Genital System
7. Bilharziasis of the lungs
  - 7.1.Pathogenesis of Lung Bilharziasis
8. Bilharziasis of other organs
9. Schistosomal antigens and immune complexes
10. Conclusion

Glossary

Bibliography

Biographical sketch

## 1. Introduction

Bilharziasis or schistosomiasis is one of the most common parasitic infection of Egyptians and also occurs in several other parts of Africa, Asia and South America. It affects more than 200 million people in at least 75 countries; mostly tropical. Schistosomal lesions – according to parasite species- primarily affect the genitourinary system or the intestinal tract. However, due to emboli of ova and/or dead worms, many other sites can be affected, as the liver, lung, and other sites. Lesions of schistosomiasis are numerous including dermatitis at the site of cercarial penetration and significant granulomatous lesions ending in fibrosis; mainly caused by ova trapped within the tissues. Dead worms cause further serious necrotizing vascular lesions. The endemicity of *the* Bilharzial disease depends on the urban disposal of urine or stools, the presence of suitable snail hosts, and the human exposure to cercariae (WHO, 1993). In Egypt, the disease was known by ancient Egyptians, thousands of years ago and was called "aaa", expressing the patient's suffering from dysuria and hematuria. Theodor Bilharz, was the first to discover the causing worms and the disease was named after this German scientist "Bilharziasis". There are five major species of *schistosoma* affecting man; *S. mansoni*, *S. hematobium*, *S. japonicum*, *S. intercalatum*, and *S. mekongi*. The first two species are the main causes of Egyptian schistosomiasis.

A.: *Schistosoma haematobium* (*S. hematobium*), that mainly infects the genitourinary system.

B.: *Schistosoma mansoni* (*S. mansoni*), that affects mainly the digestive system and liver.

### 1.2 Discovery of schistosomes ( Bilharzia worms) by Theodor Bilharz

In 1850, Professor Wilhelm Griesinger from Kiel was hired by the then viceroy of Egypt, Abbas I, as director of the Kasr El Aini medical school in Cairo along with Theodor Bilharz as his assistant. Theodor Maximilian Bilharz was a young German Pathologist from the University of Tubingen. There, he excelled at anatomy, and in addition gained an interest in helminthology from his professor, Karl Theodor von Siebold. Bilharz was at the age of 25 when he went to Egypt and whilst working in Cairo; he made his momentous discovery of *Distomum haematobium*, later renamed *Schistosoma haematobium*, as described in the main history document. By year 1852, when Bilharz discovered his parasite, he sent letters to his professor (Theodor von Siebold) in Germany, describing the new parasite during a post-mortem examination as follows; “*After my attention had been drawn to the liver, I soon found a white long helminth in the blood of the portal vein in quantity, which I assumed to be a nematode, but which I immediately recognized as something new. The microscope revealed a splendid distomum with a flat body and a curving tail which exceeded the body about ten times in length. Yet the tail was not loosely inserted like those of the cercariae but was the continued flat substance of the body of the worm itself which was rolled at the side against the abdominal surface to a half-channel*”.

He soon realized that these helminths were trematodes, with uniquely two sexes, the

flattened worms he had first seen being the males which held a single thread-like female in a fold of its body (the gynaecophoric canal), as described in a letter a few months later; “*I have not told you yet about the new phases into which my worm of the portal vein has entered. This has not developed into a fairy tail, as I had assumed, but something more miraculous- a trematode, with separate sexes. The worm which I had described to you in my last letter was the male. When I examined the intestinal veins more carefully.....,I soon found samples of the worm which harboured a grey thread in the canal of their tails. You can picture my surprise when I saw that a trematode projected out of the anterior opening of the canal*”.

He then went on describing the morphological features of this second threadlike worm, which on the basis of internal structures such as the vitellaria and ovaries, he correctly identified as the female parasite, which he named *Distomum haematobium*. The next year he described some further findings, based on more post-mortem examination:

“*Opening the urinary bladder we detected many excrescences which are unfamiliar in Europe....I cut into the largest of these excrescences and found a white thread remaining on the knife. I looked at it more closely and discovered our Distomum haematobium*”.

*He then went on describing the females , which he noted in the urinary bladder, looking different from those he had previously see:;*

“*They differ from those found in intestinal veins by the greater clarity of their inner organs..... and even more so by the immense abundance of ova, which were present in all stages of development*”

*However, even with these differences he still thought he was dealing with a single species. He also described the eggs associated with these parasites as having; “..a thin, delicate eggshell with a pointed process”*

These findings were presented, along with remarks by Prof. Theodor von Siebold, in the Journal *Zeitschrift fur Wissenschaftliche Zoologies* in 1852, as the first scientific description of this new parasitic helminth.

Bilharz also discovered the tapeworm *Hymenolepis nana*. He died at the age of 37 of typhoid fever, contracted on an expedition to the upper Nile.

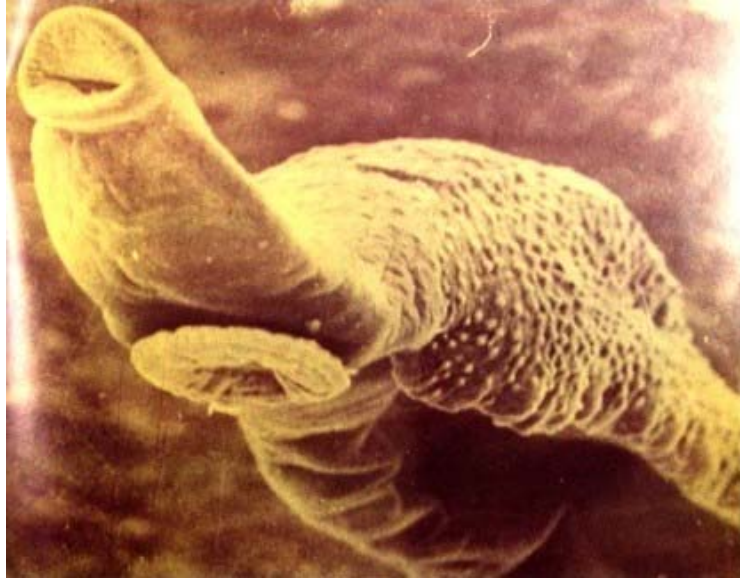

Figure 1. Bilharzia worm (Male) as appeared enlarged Thousands times by the scanning Electron Microscope, showing its two suckers and the ventral groove.




Figure 2. The German Scientist; Theodore Bilharz, who discovered Bilharzia worm in Egypt.

## 2. Life cycle of the Bilharzial parasite

### 2.1 Schistosomiasis species and their stages

The three species of schistosomiasis (*S. mansoni*, *S. haematobium* and *S. japonicum*) have similar life cycle and develop over successive stages, namely, eggs, miracidium, first stage sporocyst, second stage sporocyst, cercaria, schistosomule and adult worm. Life cycle alternates between asexual (invertebrate host) and sexual (vertebrate host) generations.

### 2.2. Asexual part of life cycle (intermediate host phase)

The eggs from an adult female in the definitive mammalian host are passed into fresh water

via the urine or stools according to the species of *Schistosoma*. Fortunate miracidia penetrate the snails, lose their cilia and metamorphose into two generations of sporocysts, which migrate to the digestive gland of the snail and mature into hundreds of fork-tailed cercariae. The intermediate host phase takes 3-5 weeks. At full maturity, cercariae emerge from the snails.

### 2.3. Sexual part of the cycle

Without successful vertebrate host contact, the cercariae will die within 48-72 hours. Following cercarial contact with the skin of vertebrate host (usually man), penetration takes place. The fork-tailed cercariae lose their tails and become known as schistosomule. They enter the lymphatics of dermis and pass to the regional lymph nodes, apparently reaching the circulation through the thoracic duct. They then pass through pulmonary circuit, from the right to the left side of the heart. The lung stage occurs 3-6 weeks after infection. Finally the schistosomule enter the systemic circulation where some reach the mesenteric vessels, while others may pass directly through the diaphragm to reach the liver. Schistosomula can only mature in intrahepatic portal veins where each schistosomule develops into an adult male or female worm. Apparently, only those worms able to pass from arterial to venous side would survive. This takes place inside the abdominal organs drained by the portal system. *Bilharzia* worms; being living in blood vessels are fed upon blood and blood constituents and that is why they excrete brown bilharzial pigment (rich in hemosiderin from red blood cells). Each worm has two suckers; one ventral and one anterior, by which it can be attached to the wall of blood vessels (see photos in section 10). Adult worms mate in the small vasculature of the liver and make a paired migration against the flow of venous blood to the predestined venous plexus. When venous caliber impedes further paired migration, the female progresses alone to mesenteric veins (*S. mansoni* and *S. japonicum*) or the veins of the vesical plexus (*S. haematobium*) where they lay their eggs. The oviposition starts 4-6 weeks after initial cercarial infection. Average number of eggs/day differs according to the species. *S. haematobium* 500-1000, *S. mansoni* 350-400 and *S. japonicum* 1500-3000 eggs/day. About 50% of the deposited eggs pass through the venules wall into the tissue, those of *S. haematobium* mainly into trapped into the bladder wall, those of *S. japonicum* and *S. mansoni* mainly into the wall of the small intestine, Large intestine respectively. They then pass through the mucosa to be excreted in urine or faeces. The remaining 50% of eggs remain trapped in the tissues of the bladder or intestine or they are swept back into the portal circulation and are trapped in the liver. Some eggs may be found also in the genital tract, lungs, central nervous system and other organs.

### 2.4. Eggs

Eggs trapped within the tissues secrete histolytic enzymes which help their passage through the tissues and they also secrete antigenic proteins which are responsible for much of the pathology of schistosomiasis.

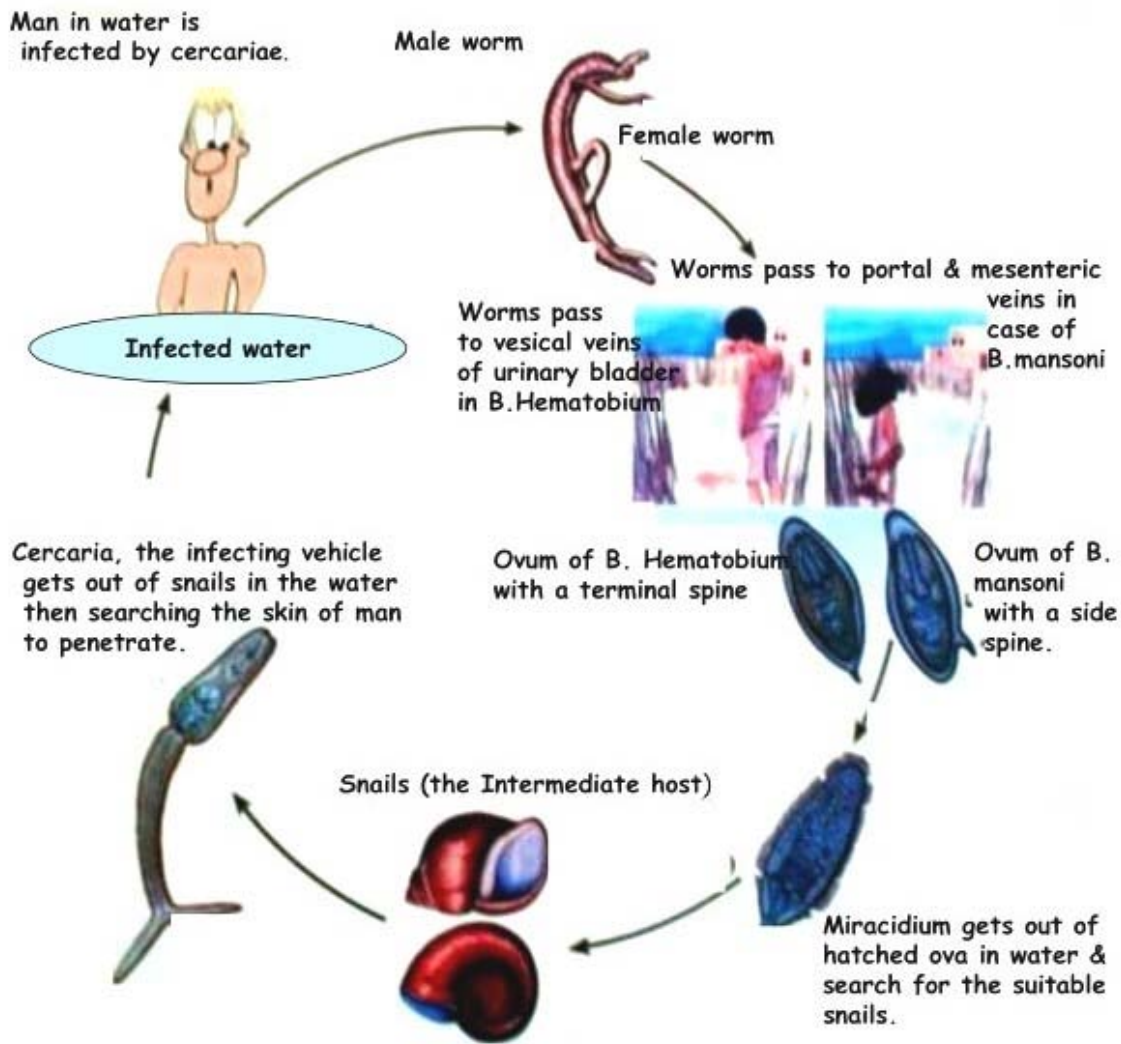


Figure 3 Life cycle of Bilharzia worm.

### 3. Pathogenesis of schistosomiasis

#### 3.1. Eggs

The schistosoma eggs in the mammalian host don't multiply and the short-lived embryos are protected from phagocytosis by the egg shells. Soon, after egg laying, the embryos mature and begin to secrete antigenic material through ultramicroscopic pores in the egg shell. These pores are also the route for nutrients and metabolites to and from the eggs and the route for the release of proteolytic enzymes responsible for eruption of eggs from the veins to the tissues. The organisms live for further 2 weeks and after their death, emission of antigen rapidly wanes.

#### 3.2. Egg granulomas

Most of the pathology of schistosomiasis results from granuloma formation around Schistosoma eggs (ova), known as periovarian granulomas whereas it has been attributed to the antigenic secretions of schistosoma eggs. Cell types in the S.mansoni granuloma vary

with prior sensitization, length of infection and the time passed after setting of eggs in the tissues.

### **3.3. Mechanisms underlying granuloma formation**

Periovular granuloma is mainly built up by a cellular mediated immune reaction. Antibody deposits are also found, probably functioning as a local humoral antibody barrier which allows a slow and progressive neutralization of antigens.

### **3.4. Pathological stages of schistosomiasis**

There are two distinct stages of schistosomiasis. The early acute stage which appears 8-12 weeks post- infection (P.I.) and is characterized by vigorous T-cell mediated granulomatous response and inflammatory lymphokine production. The chronic stage develops 16-20 weeks P.I. and is characterized by spontaneous modulation of granulomatous response with reduced lymphokine production and elevated humoral response. The acute granuloma is large and diffuse, and is usually composed of eosinophils, neutrophils and lymphocytes while chronic granuloma is small and better circumscribed and is composed of lymphocytes, macrophages, epithelioid cells, fibroblasts and multinucleated giant cells. In an experimental study in our Pathology Department in Theodor Bilharz Research Institute. We studied the different stages of schistosoma mansoni granulomas in mice and followed the different types of the deposited collagens within and around these granulomas. Groups of albino white lab-bred mice were infected by 60 cercariae each of the S.mansoni type, via tail immersion as to mimic exactly the natural infection. Sacrification of mice was performed at different weeks intervals in order to study the granulomas stages in the liver. At 5<sup>th</sup> week post infection, ova starts to appear inside the lumens of the hepatic veins as well as also the bilharzia worms. At 6<sup>th</sup> week interval, moderate sized, purely cellular granulomas starts to appear in the portal areas around the bilharzia ova. At 8<sup>th</sup> week, large mainly cellular granulomas are formed around the eggs with a loose network made of thin collagenous fibrils in the background, proved by the immunofluorescent techniques to be procollagen III and collagen III. With the progress of the Bilharzial infection, more collagen is deposited that form thick dense fibrosis, the granulomas decrease slightly in size or may become adherent or confluent together due to their crowdedness in the portal areas and their cellular contents gradually decrease in number. The immunofluorescent techniques proved that this later fibrosis is formed of collagen I. further studies proved that both procollagen III and collagen III, are reversible by anti-schistosomal treatment, while collagen I, being thick and more intense is irreversible by treatment.

## **4. Clinical features of Bilharziasis due to Schistosoma mansoni infection**

The stages schistosomiasis include invasion, maturation, acute infection and chronic infection. These stages result in three well-defined syndromes, cercarial dermatitis or swimmer's itch, acute schistosomiasis (acute bilharziasis) or Katayama fever and chronic schistosomiasis (chronic Bilharziasis).

### **4.1.Skin Lesions**

During the stage of invasion, the cercariae penetrate the skin or mucous membranes in less

than 15 minutes acting by combination of cercarial muscular action and glandular secretion. In insensitive persons, the reaction to invasion is mild and transient erythema usually appears within 12 hours and soon disappears but after repeated exposures, the skin shows itchy papules and local edema. In endemic areas, the local people often show no local skin reaction which may be a reflection of passive immunity derived from the mother, followed by active immunity in childhood. Cercarial dermatitis is likely a result of host sensitization. It's diagnosis at this stage is quite difficult and treatment is usually not advised.

#### **4.2. Acute schistosomiasis**

May develop 3-9 weeks after exposure to infection. This period coincide with the onset of egg production although the earliest phase of the syndrome can be initiated by the parasite (worm) antigens present before oviposition. The clinical severity of acute schistosomiasis is closely correlated with the intensity of *S.mansoni* infection. Elevation of serum IgG, IgE and IgM in patients indicated that the illness is associated with intense immune-activity.

##### **4.2.1. Katayama fever**

Is a form of serum sickness resulting from cross reaction between worm and egg antigens with antibody levels rising rapidly resulting in the formation of antigen-antibody immune complexes.

##### **4.2.2. Symptoms of the acute stage**

In immune persons, this stage is usually asymptomatic but in primary infection of non immune individuals, it is manifested by fever, headache, nausea, vomiting, diarrhea, dry cough, lymphadenopathy, hepatosplenomegally and peripheral eosinophilia. Symptoms last from few weeks to two or three month end gradually abate without therapeutic intervention although heavy primary infection can be fatal.

##### **4.2.3. Treatment of Acute Phase**

The best therapeutic approach to acute schistosomiasis is by the use of schistosomicides alone or in combination with steroids.

-  
-  
-

TO ACCESS ALL THE 27 PAGES OF THIS CHAPTER,  
Visit: <http://www.eolss.net/Eolss-sampleAllChapter.aspx>

#### **Bibliography**

Akl MM, Hindawi AF, Hamam OA, El-Baz AG (2001): Predictive value of Ki67 expression in schistosomal



and non-schistosomal bladder lesions in correlation to cytometric parameters. *Kasr El-Aini Medical Journal* 7(1):427-444. [The topic deals with the increased expression of nuclear proliferation marker and nuclear measurements within bladder urothelium in bilharzial lesions].

Al-Shukri S, Alwan MH, Nayef M, Rahman AA (1987): Bilharziasis in malignant tumors of the urinary bladder. *Br J Urol* 1987; 59:59. [Article dealing with malignant urinary bladder tumors are associated with high frequency of urinary Bilharziasis]

Badawi AF (1996): Molecular and genetic events in schistosomiasis-associated human bladder cancer: role of oncogenes and tumor suppressor genes. *Cancer Lett* Aug 2; 105(2): 123-38. [A topic dealing with genetic mutations excited by bilharzial infection]

Basta MT, Attallah AM, Seddek MN, *et al* (1988): Cytokeratin shedding in the urine: A biologic marker for bladder cancer? *Br J Urol* 61:116. Committee on cancer, Philadelphia, J.B. Lippincott, 1992 [A paper focusing on urinary bilharziasis as an important cause for presence of cytokeratin in urine].

Bedair AS and El Hindawi AA (1993): In situ carcinoma of the parasitic urethra in cystoprostatectomy specimens removed for bilharzial bladder carcinoma. *The New Egyptian Journal of Medicine* Vol 8(6): 1865-1871. [A paper dealing with the frequency of bilharzial affection in cases of bilharzial bladder cancer].

Burki A, Tamer M, Burnier E, *et al* (1986): comparison of ultrasonography, intravenous pyelography and cystoscopy in detection of urinary tract lesions due to *Schistosoma hematobium*. *Acta trop* 43:139. [A paper showing the frequency of bilharzial affection in cases of bilharzial bladder cancer].

Carter HB, Amberson JB, Bander NH, *et al* (1987): Newer diagnostic techniques for bladder cancer. *Urol Clin North Am* 14:763.

Cayabyab M, Harn DA (1995): Up-regulation of B7.2 expression on B cells correlates with the development of Th2 pathway in murine experimental schistosomiasis. *Am J Trop Med Hyg* 53:150. [A paper discussing the Immunopathology of experimental bilharziasis].

Chapman JW, Connolly JG, Rosenbaum L (1981): Occupational bladder cancer: A case-control study. *In* Connolly JG, ed: *Carcinoma of the Bladder*. New York, Raven Press, 1981 p 45. [A study describing how some jobs can lead to the affection by bladder cancer; working in mines and in cigarette factories.].

Chaudhary KS, Lu QL, Abdel PD, *et al*. (1997): Expression of bcl-2 and p53 oncoproteins in schistosomiasis associated transitional and squamous cell carcinoma of urinary bladder. *Br J Urol* 79: 78-84. [Description of the role of certain oncoproteins in development of bladder cancer in cases of bladder bilharziasis].

Cheever AW, Young SW, Shehata A (1975b): Calcification of *Schistosoma hematobium* eggs: Relation of radiologically demonstrable calcification to eggs in tissues and passage of eggs in urine. *Trans R Soc Trop Med Hyg* 69:410. [A Radiological demonstration of calcified eggs points to tissue eggs and decreased numbers of eggs in urine].

Cheever AW, Kamel IA, Elwi AM, *et al* (1977): *Schistosoma mansoni* and *Schistosoma hematobium* infections in Egypt: II. Quantitative parasitological findings at necropsy. *Am J Trop Med Hyg* 26:702. [Necropsy could show increased incidence of both types of bilharziasis in Egypt].

Cheever AW, Kamel IA, Elwi AM, *et al* (1978): *Schistosoma mansoni* and *Schistosoma hematobium* infections in Egypt: III. Extrahepatic pathology. *Am J Trop Med Hyg* 27:55. [A paper demonstrating that both types of bilharziasis showed extrahepatic lesions].

Cheever AW, Byram JE, Hieny S, *et al* (1985): Schistosomiasis in B-cell depleted mice. *Parasite Immunol* 7:399. [Experimental work to show pathology of bilharziasis in Immuno-suppressed mice].

Cheever AW (1986): Decalcification of schistosome eggs during staining of tissue sections: A potential source of diagnostic error. *Am J Trop Med Hyg* 35:959. [Decalcification of bilharziasis eggs during tissue staining could cause diagnostic error].

Chopin DK, Popov Z, Hoznek A, Lefrere M-A, Bellot N and Abbou C (1996): P53 and angiogenesis in invasive bladder cancer. *J Urol*, part 2 155:690A, abstract 1518. [P53 expression and angiogenesis are increased in invasive bladder cancer].

Christie JD, Crouse D, Kelada AS, *et al* (1986a): Patterns of *Schistosoma hematobium* egg distribution in the human lower urinary tract: III. Cancerous lower urinary tracts. *Am J Trop Med Hyg* 35:759. [A publication

showing how bilharzia haematobium eggs are distributed in lower urinary tract & affected by cancer bladder in small groups or as individual eggs in between tumor tissue]. Christie JD, Crouse D, Pineda J, *et al* (1986b): Patterns of *Schistosoma hematobium* egg distribution in the human lower urinary tract: I. Non-cancerous lower urinary tracts. *Am J Trop Med Hyg* 35:743. [A publication showing how bilharzias haematobium eggs are crowded and distributed mainly in submucosa in lower urinary tract affected by urinary bilharziasis].

Christie JD, Crouse D, Smith JH, *et al* (1986c): Patterns of *Schistosoma hematobium* egg distribution in the human lower urinary tract: II. Obstructive uropathy. *Am J Trop Med Hyg* 35:752. [A paper describing the crowded of bilharzia ova as well as the fibrosis in the urinary bladder wall among those case].

Cohen SM and Ellwein LB (1990): Cell proliferation in carcinogenesis. *Science* 249: 1007-1014. [A paper describing the excess of cell proliferation in cancerous cases].

Cohen SM, Ellwein LB (1991a): Cell proliferation and bladder tumor promotion. *In: Progress in Clinical and Biological Research*, Vol. 369: Chemically Induced Cell Proliferation. New York, Wiley-Liss, 1991a, pp 347-355. [Chemicals exciting cell proliferation in evolution of bladder cancer].

Cohen SM, Ellwein LB (1991b): Genetic errors, cell proliferation, and carcinogenesis. *Cancer Res* 51:6493. [Paper Discussing factors leading to carcinogenesis].

Cohen SM, Purtillo DT and Ellwein LB (1991): Pivotal role of increased cell proliferation in human carcinogenesis. *Moll Pathol* 4: 371-374. [Role of cell proliferation in tumor evolution].

Costello AJ, Tiptaft RC, England HR, *et al* (1984): Squamous cell carcinoma of the bladder. *Urology* 23:234. [The most common bladder tumor associated with urinary bilharziasis and bladder stones

Dvorak HF, Nagy JA, Dvorak AM (1991b): Structure of solid tumors and their vascularity: Implications for therapy with monoclonal antibodies. *Cancer Cells* 3:77-85. [Solid tumors show increased vascularity].

Dvorak HF, Brown LF, Detman M, Dvorak AM (1995): Vascular permeability factor/vascular endothelial growth factor, microvascular hyperpermeability and angiogenesis. *Am J Pathol* 146 (5): 1029-38. [Role of vascular endothelial growth factor in angiogenesis].

Eder IE, Stenzl A, Hobisch A, Cronaur MV, Bartsch G and Klocker H (1996): Transforming growth factor  $\beta_1$  and  $\beta_2$  in serum and urine from patients with bladder carcinoma. *J Urol* 156:953. [Biomarkes pointing to the preeence of bladder carcinoma].

Edgren M, Lennernas BO, Larsson A, Nilsson S (1999): Serum concentrations of VEGF and b-FGF in renal cell, prostate and urinary bladder carcinomas. *Anticancer Res.* 19:869-74. [The subject discusses the increased vascular markers in serum in cases of renal, prostatic and bladder carcinomas].

Edington GM, Von Lichtenberg F, Nwabuebo I, *et al* (1970): Pathologic effects of schistosomiasis in Ibadan, Western State of Nigeria: I. Incidence and intensity of infection; distribution and severity of lesions. *Am J Trop Med Hyg* 19:982. [ The sujet discusses the differences in incidence and pathology of bilharziasis in some countries].

El-Aasar AA, El-Merzabani MM, Higgy NA and Bdelkader MM (1979): A study on the aetiological factors of bilharzial bladder cancer in Egypt: Urinary  $\beta$ - glucouronidase. *Europ. J Cancer* 15:573-577. . [ The paper describes the causes of bilharzial bladder cancer with special concern on the importance of  $\beta$ - glucouronidase in urine]. El Badawi AA (1966): Bilharzial polyps of the urinary bladder. *Br J Urology*, 38:24-28. [This work describes the pathology of urinary bladder bilharzial polyps observed in cases of infection with urinary bilharziasis].

El Badawi AA (1966): Bilharzial polyps of the urinary bladder. *Br J Urology*, 38:24-28. [This work describes the pathology of urinary bladder bilharzial polyps observed in cases of infection with urinary bilharziasis].

EL-Badrawy N , Badawy AA, Mansy M, Akl M (1995): Evaluation of Colchicine Therapy in Control of Murine Schistosomal Hepatic Fibrosis. THE SRP INTERNATIONAL CONFERENCE ON SCHISTOSOMIASIS. March 12-16, 1995, Marriot Hotel, Cairo, Egypt. [This paper confirms the role of urinary bladder bilharziasis in evolution of cancer bladder].

El-Bassiouni NE, El-Sayed HH, Lotfy MG, Badawy AA, Roshdy MM, Asaad SO and Iskander IR (2001): Modulation of ABH and Lewis antigen expression in cancer bladder associated with schistosomiasis. *Kasr El-Aini Medical Journal* 7(1):201. . [ This work describes how the bilharzial infection exerts some modulation in

ABH and Lewis antigen expression accompanying the associated evolved cancer bladder].

El-Baz HG (1990): Study of HLA typing in urinary bladder schistosomiasis. MD thesis, clinical and chemical pathology. Faculty of medicine, Cairo Univ. May 1990. [This study shows that HLA typing is modulated from normal in patients suffering from urinary schistosomiasis].

El-Baz HG, Wishahi MM and Hammam OA (2000): Expression of p53 and c-erb-2 oncoproteins in chronic schistosomal urinary bladder lesions. *Kasr El Aini Med J* 6(4) [This work shows increased expression of both p53 and c-erb oncoproteins in chronic schistosomal urinary bladder lesions and are markers for early malignancy].

El Bolkainy NM and Chu EW (1991): evaluation of cytological screening for detection of bilharzial bladder cancer. National Cancer Institute, Al Ahram press, Cairo 174-180. .[This study shows the value of cytological screening of urine for detection of bilharzial bladder cancer].

El-Bolkainy MN, Mokhtar NM, Ghoneim MA, *et al* (1981): The impact of schistosomiasis on the pathology of bladder carcinoma. *Cancer* 48:2643. .[This study shows the value of cytological screening of urine for detection of bilharzial bladder cancer].

El Bolkainy MN, Tawfik HN and Kamel IA (1981c): Histopathologic classification of carcinomas in schistosomal. In detection of bladder cancer associated with schistosomiasis, 1<sup>st</sup> ed. El Bolkainy MN and Chu EW (eds). The National Cancer Institute, Cairo University. Al Ahram Press, Cairo, Egypt: 106-123. [This work describes the histopathological types of bladder cancer and the incidence of association with bilharziasis pointing to a higher incidence of association with squamous cell carcinoma]

El Bolkainy NM (1983): Schistosomiasis and bladder cancer. In Bryan GT, Cohen SM (eds): The pathology of bladder cancer. Boca Raton, Florida CRC Press 1983; 57. [This work describes all the urinary bladder pathological lesions exerted by bilharzial infection].

El-Bolkainy MN, Ghoneim MA, Mansour MA (1972): Carcinoma of the bilharzial bladder in Egypt: Clinical and pathological features. *Br J Urol* 44:561. [This work describes the clinical and pathological features of urinary bladder bilharziasis in Egypt at that time].

El-Bolkainy MN, Chu EW, Ghoneim MA, Ibrahim AS (1982): Cytologic detection of bladder cancer in rural Egyptian population infected with schistosomiasis. *Acta Cytol* 26:303. .[This paper describes how cytological techniques were helpful in detecting bladder cancer in rural population of Egypt].

Elem B, Purohit R (1983): Carcinoma of the urinary bladder in Zambia. A quantitative estimation of *Schistosoma hematobium* infection. *Br J Urol* 55:275. [This work describes how the quantitative estimation of cases with infestation by *Schistosoma hematobium* could predict the number of cases with carcinoma of the urinary bladder , in Zambia].

El-Khoby T, Galal N, Fenwick A, Barakat R, El-Hawey A, Nooman Z, Habib M, Abdel-Wahab F, Gabr NS, Hammam HM, Hussein MH, Mikhail NN, Cline BL, Strickland GT (2000): The epidemiology of schistosomiasis in Egypt: summary findings in nine governorates. *Am J Trop Med Hyg* 62 (2 Suppl):88-99 [This study tried to evaluate the extent of spread of schistosomiasis in 9 governorates in Egypt].

Elwi AM (1976): Pathology of Schistosomiasis. In compiled review on Schistosomiasis. Published by National Information and Documental Center, Dokki, Giza, Egypt 223-244. [This study describes the wide pathological lesions exerted by the schistosomal disease in the human body].

Feldmeier H, Gastl GA, Poggensee U, *et al* (1988): Immune response in chronic schistosomiasis hematobium and mansoni. Reversibility of alterations after anti-parasitic treatment with praziquantel. *Scand J* 28:147. [This study shows that the praziquantel treatment of bilharziasis can lead to the reversibility of the alterations in the immune response, exerted by the disease].

Foydart JM, Bere EW, Year M, *et al* (1980): Distribution in immunoelectron microscopic localization of laminin: A non-collagenous basement membrane glycoprotein. *Lab Invest* 42:336. [The study describes the increased distribution of the glycoprotein; laminin as detected by the immunoelectron microscopic studies].

Fradet Y, Cordon-Cardo C (1993): Critical appraisal of tumor markers in bladder cancer. *Semin Urol* 11:145. [The paper discusses the importance of detection of some tumor markers in cases of cancer bladder]. [The work discusses the effect of production of VEGF by the tumors on the functional maturation of dendritic cells]

Gabrilovich DI, Chen HL, Girgis KR, Cunningham HT, Meny GM, Nadaf S, Kavanaugh D, Carbone DP (1996): Production of vascular endothelial growth factor by human tumors inhibits the functional maturation of dendritic cells. *Nat Med* 2: 1096-103.

Gad El-Mawla N, El-Bolkainy MN, Khaled HM (2001): Bladder cancer in Africa: update. *Semin Oncol* 28: 174-8. [A global view of the situation of the bladder cancer in african countries].

Hang LM, Boros DL, Warren KS (1974): Introduction of Immunologic hyporesponsiveness to granulomatous hypersensitivity in *Schistosoma mansoni* infection. *J Infect Dis* 130:515. Immunologic response could be minimized in cases of granulomatous hypersensitivity in *S.mansoni* infection].

Hicks RM, Ismail MM, Walters CL, *et al* (1982): Association of bacteriuria and urinary nitrosamine formation with *Schistosoma hematobium* infection in the Qalyub area of Egypt. *Trans R Soc Trop Med Hyg* 76:519. .[ Bacteriuria that occur in the bladder infected with Schis. *Haematobium* can lead to the formation of nitrosamine compounds that can lead to the transformation of the bladder urothelium]

Journal *Zeitschrift fur Wissenschaftliche Zoologies* (1852).

Koch A, Harlow L, Haines G, Amento E, Unemori E, Wong W, Pope R, Ferrara N (1994): Vascular endothelial growth factor, a cytokine modulating endothelial function in rheumatoid arthritis. *J Immunol* 152:4149-4156 [This work discusses the role of the vascular endothelial factor in changing the endothelial function in rheumatoid arthritis].

Konchuba AM, Schellhammer PF, Alexander JP, *et al* (1989): Flow cytometric study comparing paired bladder washing and voided urine for bladder cancer detection. *Urology* 33:89. [This work discusses the importance of performance of a highly sensitive technique using the Flowcytometry in order to detect early bladder Cancer].

Koraitim MM; Metwalli NE; Atta MA; el-Sadr AA (1995): Changing age incidence and pathological types of schistosoma-associated bladder carcinoma. *J Urol* 154(5): 1714-6 [The paper shows that the age incidence of bladder cancer is changing from occurrence in rather younger age to older age ].

Korman HJ, Peabody JO, Cerry JC, *et al* (1996): Autocrine motility factor receptor as a possible urine marker for transitional cell carcinoma of the bladder. *J Urol* 155:347-349. [This paper discusses the possibility of the use of the autocrine motility factor receptor a a urine marker for bladder cancer].

Koroltchouk V, Stanley K, Stjernsward J, Mott K (1987): Bladder cancer: Approaches to prevention and control. *Bull WHO* 65:513. [This work explains different methods for prevention and control of the bilharzial disease].

Koss LG, Bartels P, Bibbo M and Taylor J (1975): Computer discrimination between benign and malignant urothelial cells. *Acta Cytol. Vol* 19(4): 378-391. [The work discusses the elaboration of new computerized techniques (by that time) to differentiate between benign & malignant epithelial cells lining the urinary bladder especially in early cases].

Koss LG, Wersto RP, Simmons DA, *et al* (1989): Predictive value of DNA measurements in bladder washings: Comparison of flow cytometry, image cytophotometry, and cytology in patients with a past history of urothelial tumors. *Cancer* 64:916. .[ This work discusses the use of two different recent advanced techniques in diagnosing bladder cancer through urine examination and describing the advantages & disadvantages of each technique, comparing it in the same time to the conventional cytologic technique of urine examination].

Kroft SH and Oyasu R (1994): Urinary bladder cancers: Mechanisms of development and progression. *Lab Invest.* 71:158-174. [The work discusses the process of carcinogenesis of the urinary bladder and how it is initiated from the continuous irritative stimulation by infection].

Ladoux A, Frelin C (1993): Hypoxia is a strong inducer of vascular endothelial growth factor mRNA expression in the heart. *Biochem Biophys Res Commun* 195:1005-1010 [This paper discusses the effect of hypoxia on the production of vascular endothelial growth factor mRNA in the heart].

Lamph W, Walmsley P, Gassone-Corsi P, Verma I (1988): Induction of proto-oncogene JUN/AP-1 by serum and TPA. *Nature* 334:629. [ Proto-oncogene JUN/AP-1 could be induced through giving certain biological materials].

Lamm DL, Griffith JG (1992): Intravesical therapy: Does it affect the natural history of superficial bladder

cancer? *Semin Urol* 10:39 [This paper discusses the effect of local treatment of superficial bladder cancer, preventing it from progression to invade the bladder wall].

Lehman JS Jr, Farid Z, Smith JH, *et al* (1973): Urinary schistosomiasis in Egypt: Clinical, radiological, bacteriological and parasitological correlations. *Trans R Soc Trop Med Hyg* 67:384. [This work shows the importance of the radiological and laboratory investigations performed in the disease of urinary bilharzias and how they are becoming well correlated with the clinical features of the disease].

Lucas S (1982): Squamous cell carcinoma of the bladder and schistosomiasis. *East Afr Med J* 59:345. [This work discusses the frequent association of squamous cell carcinoma of the bladder with bladder bilharzias due to the continuous irritation of its lining urothelial cells with the bilharzias ova leading to the transformation of these cells to another type of epithelium; more protective but in abnormal site (squamous epithelium) and then after, evolution of the squamous cell carcinoma].

Lynch CF, Cohen MB (1995): Urinary system. *Cancer* 75(suppl):316. [Discusses the urinary system and different types of evolved cancer].

Mostafa MH, Helmi S, Badawi AF, *et al* (1994): Nitrate, nitrite and volatile N-nitroso compounds in the urine of *Schistosoma hematobium* and *Schistosoma mansoni* infected patients. *Carcinogenesis* 1994; 15:619. This paper shows that produced nitrite and volatile N-nitroso compounds in urine of infected patients; which are carcinogenic could be traced in urine of those patients to follow them up].

Mostafa MH; Sheweita SA; O'Connor PJ (1999): Relationship between schistosomiasis and bladder cancer. *Clin Microbiol Rev* 12(1): 97-111. [This paper discusses the factors involved in the evolution of bladder cancer in bladder bilharzias].

Neill PJG, Smith JH, Doughty B, Kemp WM (1988): Ultrastructure of the *Schistosoma mansoni* egg. *Am J Trop Med Hyg* 39:52 [This paper shows the pictures of the egg of the bilharzial mansoni worm greatly enlarged by the electron microscope in order to show all its details and the shell pores].

Orihuela E, Shahon RS (1987): Influence of blood group type on the natural history of superficial bladder cancer. *J Urol* 138:758. [Some patients with certain blood groups are more prone to bladder cancer evolution when infected by urinary bilharzias].

Patil KP, Ibrahim AI, Shetty SD, *et al* (1992): Specific investigations in chronic urinary bilharzias. *Urology* 40:117. [Chronic urinary bilharzias infection needs specific immunological investigations to be discovered].

Robbins SL, Cotran RS and Kumar V (1994): Robbins pathologic basis of disease. 5<sup>th</sup> ed WB Saunders Company USA: chapter 21

Rosin MP, Anwar WA, Ward AJ (1994a): Inflammation, chromosomal instability, and cancer: The schistosomiasis model. *Cancer Res* 54:1929S. [Chromosomal studies of patients infected with urinary bilharzias and cancer bladder shows identified chromosomal instability].

Rosin MP, Saad el Din Zaki S, Ward AJ, Anwar WA (1994b): Involvement of inflammatory reactions and elevated cell proliferation in development of bladder cancer in schistosomiasis patients. *Mutat Res* 305:283. [This work shows frequent association of inflammatory reactions and high incidence of urothelial cell proliferation in cases with evolved cancer bladder on top of urinary bilharzias].

Rousset JJ, Houin R, Buttner A (1962): Acido-alcoholo resistance de divers oeufs de schistosomas. *Ann Parasit Hum Comp* 37:866.

Smith JH, Von Lichtenberg F (1976): Tissue degradation of calcific *Schistosoma hematobium* eggs. *Am J Trop Med Hyg* 25:595. [This paper shows that the calcified eggs of bilharzial bladder could be broken into very small pieces and degraded within the bladder tissue].

Smith JH, Elwi A, Kamel IA, Von Lichtenberg F (1974a): A quantitative post mortem analysis of urinary schistosomiasis in Egypt: I. Pathology and pathogenesis. *Am J Trop Med Hyg* 23:1054. [This work shows how post-mortem analysis for various diseases could discover more bilharzial cases that might not be discovered clinically and is considered a good method for studying the detailed pathology and pathogenesis of the disease].

Smith JH, Elwi A, Kamel IA, Von Lichtenberg F (1975): A quantitative post mortem analysis of urinary schistosomiasis in Egypt: II. Evolution and epidemiology. *Am J Trop Med Hyg* 24:806. [Post-mortem analysis of patients with urinary bilharzias provide a good method for evaluation of the epidemiology of the

disease].

Smith JH, Kelada AS, Khalil A (1977a): Schistosomal ulceration of the urinary bladder. *Am J Trop Med Hyg* 26:89. A paper that describes how the crowding of the bilharzia ova inside the superficial lining of the bladder wall could induce specific bilharzial ulcers].

Smith JH, Torky H, Kelada AS, Farid Z (1977b): Schistosomal polyposis of the urinary bladder. *Am J Trop Med Hyg* 26:85. [This paper describes the exact features of the bladder poyps exerted by bilharzial infection].

Mansy S, El-Badrawy N, Nada G, El-Garem A, Akl M, Abdel-Hady A, El-Mohandess M, Abdel-Ghany A, Voss B and Tawfik M(1990): Immunolocalization of type III procollagen in hepatosplenic schistosomiasis. *Egypt. J. Bilh. , 12 ( 1 - 2 ) : 93*. [This paper shows the localization of the increased procollagen III (a type of early fibrosis) within the hepatic tissue in hepatic bilharziasis].

Thomas JE, Bassett MT, Sigola LB, Taylor P (1990): Relationship between bladder cancer incidence, *Schistosoma hematobium* infection, and geographical region in Zimbabwe. *Trans R Soc Trop Med Hyg* 84:551. [This is a regional study in Zimbabwe to find out that there is a relatively higher incidence of association between bilharzias hematobium and the evolution of cancer bladder].

Tricker AR, Mostafa MH, Spiegelhalter B, *et al* (1989): Urinary excretion of nitrate, nitrite and *N*-nitroso compounds in schistosomiasis and bilharzial bladder cancer patients. *Carcinogenesis* 10:547. .[This paper displays the role of nitrite and *N*-nitroso compounds in bilharzial bladder in evolution of bladder cancer].

Tricker AR, Mostafa MH, Spiegelhalter B, Preussmann R (1991): Urinary nitrate, nitrite and *N*-nitroso compounds in bladder cancer patients with schistosomiasis (bilharzia). *IARC Sci Publ* (105):178-181. .[ This paper also displays the role of nitrite and *N*-nitroso compounds in bilharzial bladder in evolution of bladder cancer].

Tungekar MF, Al-Adnani MS (1986): Sarcomas of the bladder and prostate: The role of immunohistochemistry and ultrastructure in diagnosis. *Eur Urol* 12:180. [This paper discusses the role of certain laboratory techniques as immunohistochemistry and electron microscopic study in diagnosing sarcomas of the urinary bladder and prostate].

Tungekar MF, Gatter KC, Al-Adnani MS (1987): Schistosomiasis-associated squamous lesions of the bladder. Expression of low molecular weight cytokeratin proteins. *Br J Urol* 60:423. .[This paper discovered the expression of low molecular weight cytokeratin proteins in bladder bilharzial patients showing squamous bilharzial lesions].

Tungekar MF, Gatter KC, Al-Adnani MS (1988b): Immunohistochemistry of cytokeratin proteins in squamous and transitional cell lesions of the urinary tract. *J Clin Path* 41:1288. . [ This work shows also cytokeratin proteins ( in bladder tissues by immunohistochemistry), in both squamous and transitional cell lesions of the urinary tract].

Von Lichtenberg F, Edington GM, Nwabuebo I, *et al* (1971): Pathologic effects of schistosomiasis in Ibadan, Western State of Nigeria: II. Pathogenesis of lesions of the bladder and ureters. *Am J Trop Med Hyg* 20:244. . [This paper shows that bladder and ureteric bilharziasis can lead to serious urinary tract obstructive effects].

Von Lichtenberg F (1962): Host response to eggs of *Schistosoma mansoni*: I. Granuloma formation in the unsensitized laboratory mouse. *Am J Pathol* 41:711. [This work describes the host response to bilharzia eggs by inflammatory cell recruitment through stimulation by the egg antigens].

Von Lichtenberg F (1964): Studies on granuloma formation: III. Antigen sequestration and destruction in the schistosome pseudotubercle. *Am J Pathol* 45:75. [This work shows how bilharzial granulomas are formed through cell recruitment stimulation by the egg antigen].

Von Lichtenberg F (1973): Comparative histopathology of schistosome granulomas in the hamster. *Am J Pathol* 72:149. [This work was performed to study bilharzial granuloma cellular constituents in hamsters in an experimental work].

Wishahi M, el-Baz HG, Shaker ZA (1989): Association of HLA-A, B, C and DR antigens and clinical manifestations of *schistosoma hematobium* in the bladder. *Eur Urol* 16:138. [This work shows that Human Leukocytic Antigen and Drug resistant antigens types are associated with bladder bilharziasis].

Wynn T *et al* (1995): An IL-12-based vaccination method for preventing fibrosis induced by schistosome infection. *Nature* 376:594. [This work shows that the use of Interleukin 12 can prevent fibrosis, that excited by

bilharzial infection].

### **Biographical Sketch**

**Dr. Maha Mahmoud Akl**, born in Cairo, Egypt 19/07/1952, is a medical graduate, from Cairo University. She pursued her postgraduate studies and training in Kasr El Ainy Teaching Hospital, which is the main teaching hospital for Cairo University. She was appointed in the Pathology Department, Theodor Bilharz Research Institute affiliated to the Ministry of High Education & Scientific Research as a Pathology instructor 1977 –1982, Assistant lecturer .in 1983 and in 1987 became an Ass.Prof. Of Pathology: She was appointed as Professor of Pathology in 1997.

From 1994-2006 she became the HEAD OF PATHOLOGY Department of Theodor Bilharz Research Institute, In 1988, she was appointed as a Scientific Supervisor on the Unit of Scientific & Cultural Relationship of the Institute. In 2001 she was appointed as the head of Lagnet Al Efad of the Institute. In 2002, became a member in the Council for judging Promotion of the Staff Members into Ass.Professors & Professors.

Prof. AKI is a member of the Egyptian Association of Laboratory Medicine, and a member of the Egyptian Society of Pathologists as well as a member of both the Arab division of the International Academy of Pathology and a member of the European Society of Pathology. At present (2006), she is the Head of Pathology Department in Theodor Bilharz Research Institute since 1994-present.